

Читать  
онлайн  
Read  
online

Ekaterina V. Ulanovskaya<sup>1</sup>, Aleksandr A. Kovshov<sup>1,2</sup>, Victor V. Shilov<sup>1,2</sup>,  
Aleksandr N. Nikanov<sup>1</sup>, Nadezhda I. Kuprina<sup>1</sup>

## Features of the course of occupational upper limb myofibrosis in patients with generalized polyosteoarthritis

<sup>1</sup>North-West Public Health Research Center, Saint-Petersburg, 191036, Russian Federation;

<sup>2</sup>North-Western State Medical University named after I.I. Mechnikov, St. Petersburg, 191015, Russian Federation

**Introduction.** Occupational diseases of the upper extremities from physical (functional) overstrain occupy a leading place in the structure of occupational morbidity, with myofibrosis being the most common disease.

**The aim of the study** was to assess the course of myofibrosis against the background of generalized polyosteoarthritis using the ultrasound method.

**Materials and methods.** One hundred seventeen mining industry workers were examined. The main group consisted of 20 patients with an established diagnosis of 1<sup>st</sup> stage of myofibrosis and generalized osteoarthritis, the control group consisted of 97 patients with an established diagnosis of 1<sup>st</sup> stage of myofibrosis. Standard clinical and laboratory methods of examination, ultrasound examination of the muscles of the forearms and shoulders were performed.

**Results.** The median values of epimysium and muscle bundles thickness in both the main and control groups correspond to stage 1 of myofibrosis, while the median thickness of perimysium in the reference group corresponds to stage 1, and in main group it corresponds to stage 2. In addition, the 75<sup>th</sup> percentile of epimysium thickness, as well as the 25<sup>th</sup> percentile of muscle bundle thickness in the main group, also meet the criteria for stage 2 of myofibrosis.

**Limitations.** The study has gender restrictions (men were investigated), as well as restrictions on professions (mining workers).

**Conclusions.** According to the results of ultrasound examination, in the main group patients there are signs corresponding to the transition of myofibrosis to the second stage, which is characterized by a statistically significant increase in perimysium thickness, as well as a pronounced tendency of epimysium thickness increase and reduce of muscle bundle thickness. This is important when the disease is associated with occupation, allowing patients with a combination of myofibrosis and generalized osteoarthritis to establish a more severe stage of myofibrosis course, indicating a more pronounced degree of occupational work ability loss.

**Keyword:** ultrasound examination; upper limb muscles; myofibrosis; generalized osteoarthritis

**Compliance with ethical standards.** The Local ethics committee of North-West Public Health Research Center approved this study (minutes of the meeting No. 2022/50.2 from 28.12.2022). All research participants gave voluntary informed consent to participate in this study.

**For citation:** Ulanovskaya E.V., Kovshov A.A., Shilov V.V., Nikanov A.N., Kuprina N.I. Features of the course of occupational upper limb myofibrosis in patients with generalized polyosteoarthritis. *Gigiena i Sanitariya (Hygiene and Sanitation, Russian journal)*. 2023; 102(9): 941-946. <https://doi.org/10.47470/0016-9900-2023-102-9-941-946> <https://elibrary.ru/zyeude>

**For correspondence:** Ekaterina V. Ulanovskaya, MD, PhD, head of the radiology department of North-West Public Health Research Center, Saint-Petersburg, 191036, Russian Federation. Email: rentgen\_s-znc@mail.ru

### Information about authors:

Ulanovskaya E.V., <https://orcid.org/0000-0001-9583-0522>

Shilov V.V., <https://orcid.org/0000-0003-3256-2609>

Kuprina N.I., <https://orcid.org/0000-0002-1468-3186>

Kovshov A.A., <https://orcid.org/0000-0001-9453-8431>

Nikanov A.N., <https://orcid.org/0000-0003-3335-4721>

**Contribution:** Ulanovskaya E.V. – Concept and design of the study, data collection and processing, text writing; Shilov V.V. – Concept and design of the study, editing; Kovshov A.A. – data statistical processing, editing; Nikanov A.N. – editing; Kuprina N.I. – data collection. All co-authors – approval of the final version of the article, responsibility for the integrity of all parts of the article. All authors are responsible for the integrity of all parts of the manuscript and approval of the manuscript final version.

**Conflict of interest.** The authors declare no conflict of interest.

**Acknowledgement.** The study had no sponsorship.

Received: May 24, 2023 / Accepted: September 26, 2023 / Published: October 30, 2023

Улановская Е.В.<sup>1</sup>, Ковшов А.А.<sup>1,2</sup>, Шилов В.В.<sup>1,2</sup>, Никанов А.Н.<sup>1</sup>, Куприна Н.И.<sup>1</sup>

## Особенности течения профессионального миофиброза верхних конечностей у пациентов с генерализованным полиостеоартритом

<sup>1</sup>ФБУН «Северо-Западный научный центр гигиены и общественного здоровья» Роспотребнадзора, 191036, Санкт-Петербург, Россия;

<sup>2</sup>ФГБОУ ВО «Северо-Западный государственный медицинский университет имени И.И. Мечникова» Министерства здравоохранения Российской Федерации, 191015, Санкт-Петербург, Россия

**Введение.** Профессиональные заболевания верхних конечностей от физического (функционального) перенапряжения занимают ведущее место в структуре профессиональной заболеваемости, при этом наиболее частым заболеванием является миофиброз.

**Цель исследования** – повысить эффективность диагностики профессионального миофиброза на фоне генерализованного остеоартрита с помощью метода ультразвукового исследования.

**Материалы и методы.** Обследованы 117 работников горнодобывающей промышленности, из которых основную группу составили 20 пациентов с установленным диагнозом миофиброза 1-й стадии и генерализованного остеоартрита, контрольную группу составили 97 пациентов с установленным диагнозом миофиброза 1-й стадии. Использовались стандартные клинико-лабораторные методы исследования, ультразвуковое исследование мышц предплечий и плеч.

**Результаты.** Медианные значения толщины эпимизия и мышечных пучков как в основной, так и в контрольной группах соответствуют 1-й стадии миофиброза, тогда как медиана толщины перимизия в контрольной группе соответствует 1-й стадии, а в основной – 2-й стадии. Кроме того, 75-й процентиль толщины эпимизия, а также 25-й процентиль толщины мышечного пучка в основной группе также соответствуют критериям 2-й стадии миофиброза.

**Ограничения исследования.** Исследование имеет гендерные ограничения (обследовались мужчины), а также ограничения по профессиям (работники горнодобывающей промышленности).

**Заключение.** По результатам ультразвукового исследования у пациентов основной группы отмечаются признаки, соответствующие переходу миофиброза во вторую стадию, что характеризуется статистически значимым увеличением толщины перимизия, а также выраженной тенденцией к увеличению толщины эпимизия и уменьшению толщины мышечного пучка. Это имеет существенное значение при проведении экспертизы связи заболевания с профессией, позволяя у пациентов с сочетанием миофиброза и генерализованного остеоартрита установить более тяжёлую стадию течения миофиброза, свидетельствующую о более выраженной степени утраты профессиональной трудоспособности.

**Ключевые слова:** ультразвуковое исследование; мышцы верхних конечностей; миофиброз; генерализованный остеоартрит

**Соблюдение этических стандартов.** Исследование одобрено локальным этическим комитетом ФБУН «СЗНЦ гигиены и общественного здоровья» (Протокол заседания № 2022/50.2 от 28.12.2022 г.). У всех пациентов было получено добровольное информированное согласие на участие в данном исследовании.

**Для цитирования:** Улановская Е.В., Ковшов А.А., Шилов В.В., Никанов А.Н., Куприна Н.И. Особенности течения профессионального миофиброза верхних конечностей у пациентов с генерализованным полиостеоартритом. *Гигиена и санитария*. 2023; 102(9): 941-946. <https://doi.org/10.47470/0016-9900-2023-102-9-941-946> <https://elibrary.ru/yzeuide> (на англ.)

**Для корреспонденции:** Улановская Екатерина Владимировна, канд. мед. наук, зав. кабинетом лучевой диагностики ФБУН «Северо-Западный научный центр гигиены и общественного здоровья». Email: rentgen\_s-znc@mail.ru

**Участие авторов:** Улановская Е.В. – концепция и дизайн исследования, сбор и обработка данных, написание текста; Ковшов А.А. – статистическая обработка материала, редактирование; Шилов В.В. – концепция и дизайн исследования, редактирование; Никанов А.Н. – редактирование; Куприна Н.И. – сбор материала. Все соавторы – утверждение окончательного варианта статьи, ответственность за целостность всех частей статьи.

**Конфликт интересов.** Авторы декларируют отсутствие явных и потенциальных конфликтов интересов в связи с публикацией данной статьи.

**Финансирование.** Исследование не имело спонсорской поддержки.

Поступила: 24.05.2023 / Принята к печати: 26.09.2023 / Опубликовано: 30.10.2023

## Introduction

According to the data of the State Report “On the state of sanitary and epidemiological welfare of population in Russian Federation in 2021”, in the structure of occupational pathology, depending on the influencing factors of the labor process, diseases associated with physical overload and functional overstrain occupy the second place and amount to 16.74% [1].

Occupational diseases of upper extremities from physical (functional) overstrain according to the List of occupational diseases (Appendix to the Order of the Ministry of Health and the SR of Russia dated 27.04.2012 No. 417n) are represented by such diseases of the musculoskeletal system and connective tissue as chronic myofibrosis of the forearm and shoulder, tendovaginitis, stenosing ligamentosis, periarthrosis, epicondylosis, deforming osteoarthritis, bursitis, aseptic necrosis<sup>1</sup>. This pathology occupies a leading place in the structure of occupational morbidity not only in Russian Federation, but also in some countries of Europe and Far East (from 17.8% to 49.9% in some regions) [2–4]. At the same time, the most common disease is myofibrosis. The widespread distribution of musculoskeletal system occupational diseases is due to the use of manual labor in 54.5% of professions, of which 48% belong to the category of severe [5, 6].

Osteoarthritis is a group of diseases of various etiologies with similar clinical manifestations and outcomes, which are based on the defeat of all components of the joint: cartilage, synovial membrane, ligaments, capsules, as well as periarticular muscles [7, 8]. According to Russian Ministry of Health, the number of patients with osteoarthritis has increased by 3.7% over the past 5 years and amounted to 4.3 million people [9]. It should be understood that these figures reflect only officially registered cases, and the true number of cases may be much higher.

According to our data, in the year 2022, 251 patients out of 653 undergoing the examination procedure on the connection of the disease with a profession at North-West Public Health Research Center, had a concomitant diagnosis of generalized polyosteoarthritis. These figures show that the combination of occupational myofibrosis with generalized polyosteoarthritis is the most common in the practice of an occupational pathologist.

When studying the instrumental diagnosis of occupational myofibrosis in the available literature, we were able to find only

few publications on the study of the ultrasound method and all of them were based on a qualitative assessment of pathological changes [10, 11]. The existing data are insufficiently systematized and are sometimes contradictory, which makes it difficult to assess the connection of this disease with professional activity. Therefore, we decided to develop objective quantitative criteria for assessing the severity of the course of this disease ourselves and give a complete ultrasound picture of changes in the muscles [12, 13].

In this paper, we decided to expand the existing accumulated experience in the modern diagnosis of occupational myofibrosis and evaluate the course of this disease in patients with generalized osteoarthritis.

*The aim of the study* is to increase the effectiveness of occupational myofibrosis diagnosis against the background of generalized osteoarthritis using the ultrasound method.

## Materials and methods

In the course of the work, 117 mining industry workers were examined, where the main group consisted of 20 patients with an established diagnosis of stage 1 myofibrosis and generalized osteoarthritis, the reference group consisted of 97 patients with an established diagnosis of stage 1 myofibrosis. The examination of patients was carried out in the clinic of occupational pathology in North-West Public Health Research Center in 2022.

The main group included 20 men with established diagnoses of stage 1 occupational myofibrosis and generalized osteoarthritis. Patients worked in the mining industry in the professions of a drifter, an underground miner, a machinist of mining excavation machines, drivers of heavy trucks.

The reference group consisted of 97 patients (men) with an established diagnosis of stage 1 occupational myofibrosis with identical working conditions, work experience and age. The study did not include patients with confirmed systemic diseases (rheumatoid arthritis, systemic scleroderma, etc.), post-traumatic deforming arthrosis, endocrine diseases, and infectious arthritis.

The nature of labor activity was assessed according to the data of sanitary and hygienic characteristics of working conditions of employees compiled by the departments of the Russian Federal Service for surveillance on consumer rights protection and human wellbeing (Rospotrebnadzor) for the subject of Russian Federation or their structural divisions if an employee is suspected of having an occupational disease.

The data on patients health state of were obtained during the in-depth clinical and instrumental examination on the basis of North-West Public Health Research Center. The examination was

<sup>1</sup> Order of the Ministry of Health and Social Development of the Russian Federation No. 417n dated April 27, 2012 “On Approval of the list of occupational diseases” (registered with the Ministry of Justice of the Russian Federation on May 15, 2012 No. 24168). Access mode: [https://www.consultant.ru/document/cons\\_doc\\_law\\_129943/](https://www.consultant.ru/document/cons_doc_law_129943/) (in Russian)

Table 1 / Таблица 1

**Diagnostic criteria for determining the stage of occupational myofibrosis****Диагностические критерии для определения стадии профессионального миофиброза**

Stages of the pathological process Стадии патологического процесса	Thickness of Epimysium Толщина эпимизия			Thickness of perimysium Толщина перимизия			Thickness of muscle bundle Толщина мышечного пучка		
	mm / мм	Me	IQR	mm / мм	Me	IQR	mm / мм	Me	IQR
Standard / Норма	0.5–0.6	0.6	0.6–0.5	0.5–0.6	0.6	0.6–0.5	1.3–2.2	1.8	2.0–1.5
1 <sup>st</sup> stage / 1-я стадия	0.7–0.8	0.7	0.8–0.7	0.7–0.8	0.8	0.8–0.7	1.1–1.2	1.2	1.2–1.1
2 <sup>nd</sup> stage / 2-я стадия	0.9–1.0	0.9	1.0–0.9	0.9–1.0	1.0	1.0–0.9	1.0–0.9	1.0	1.1–0.9
3 <sup>rd</sup> stage / 3-я стадия	от 1.1	1.3	1.3–1.2	от 1.1	1.3	1.3–1.2	0.8–0.6	0.7	0.7–0.6

Note: Me – median; IQR – interquartile range.

Примечание. Me – медиана; IQR – межквартильный диапазон.

carried out by specialist doctors (surgeon, neurologist, therapist, ophthalmologist, otorhinolaryngologist, and occupational pathologist), standard laboratory tests were performed, ultrasound scanning of upper extremities muscles.

Ultrasound scanning was performed in the clinic of occupational pathology on a Samsung Medison HS-50 device with a linear sensor at an operating frequency of 5–15 MHz at a depth of up to 3.5–4.0 cm according to the standard procedure. The study was carried out in a supine position with arms stretched out along the trunk. The linear sensor was installed in the anterior longitudinal position in the projection of the shoulder joint. This projection allows to evaluate the articular gap, the contours of the heads of humeral and radial bones, the condition of the cartilage. Next, the sensor moves distally and longitudinally along the muscle abdomen with an assessment of internal structures: skin, subcutaneous fat, epimysium, muscle bundles, perimysium and the uniformity of the muscle as a whole. All measurements were also carried out on the contralateral side. To study deep muscles, the patient's position remained the same, the tilt of the sensor was changed using "fan-like movements". A similar technique was used to study the muscles on the contralateral side [12–14]. Ultrasound criteria for the stages of myofibrosis are presented in Table 1 [13].

Statistical processing of the research results was carried out using the IBM SPSS Statistics v.22 software product and Microsoft Office Excel 2013. Descriptive statistics of age and work experience included the arithmetic mean and standard error of the mean, symptoms and signs – the relative frequency of the trait in the study sample and 95% confidence interval (95% CI) according to the Wilson method. Descriptive statistics of ultrasound signs are represented by the median, 25<sup>th</sup> and 75<sup>th</sup> percentile (interquartile range). The normality of the distribution in the samples of the main group was determined using the Shapiro-Wilk criterion, the reference group – the Kolmogorov-Smirnov single-sample criterion. Due to the fact that the distribution in all samples of the reference group, including the results of ultrasound (thickness of the epimysium, perimysium and muscle bundle), as well as in the sample «thickness of the muscle bundle» of the main group, differed from normal, the Mann-Whitney criterion was used to compare the medians of the thickness of the muscle structures in the main and reference groups. The critical significance level of the null hypothesis was assumed to be 0.05.

## Results

As a result of the conducted studies, it was found that in both groups the average age of patients was 48±9.8 years. The work experience under the influence of harmful production factors that could cause occupational disease was 12.5±3.2 years. The class of working conditions at the workplaces of a drifter, an underground miner, a driver of mining excavation machines, drivers of heavy-duty vehicles was at least 3.1 (harmful working conditions of the 1st degree)<sup>2</sup>. The leading harmful production factor determining

the final class of working conditions was the severity of the labor process, characterized by increased static loads, the mass of manually lifted and moved cargo, and stereotypical working movements.

The data of objective examination of patients in reference and main groups are represented in Table 2.

As can be seen from the data presented in the table, the most common type of complaint of patients in the reference group was soreness in the muscles of the forearms and shoulders (97 people). It is typically that the pain was felt in 25.8% of cases at the end of the working shift and was constant in 73.2% of cases. A decrease in muscle strength was noted by 95.9% of workers, and a violation of fine motor skills – 74.2%. On objective examination, it is clear that 100% had pain during palpation, 61.9% had muscle tissue sealing, heaviness during palpation was noted only in 36.1% of cases. A decrease in muscle strength was recorded in 80.4%, in most cases muscle strength was reduced moderately.

Among the patients of the main group, in addition to complaints of pain in the muscles of the forearms and shoulders, in 100% of cases there were also complaints of pain in 3 or more joints, in 70% – stiffness in the joints. During an objective examination, joint deformity was observed in 70% of cases, while according to the results of dynamometry, a significant decrease in muscle strength was recorded in 30% of patients.

With a 95% probability, statistically significant differences in the frequency of complaints in the main and control groups were established for two complaints (pain in 3 or more joints, stiffness in the joints), as well as for two clinical signs on palpation of the joints (soreness in 3 and more joints, joint deformation). The frequency of all other complaints in the main and control groups according to Table 2 did not have statistically significant differences.

The results of blood laboratory tests in both groups showed no significant deviations from the standart.

The typically ultrasound signs of myofibrosis are an increase of epimysium and perimysium thickness with a simultaneous decrease of the muscle bundles thickness [12, 13]. The changes specific to myofibrosis of the 1<sup>st</sup> stage are shown in Figure 1.

In Figure 1, the total echogenicity of the muscle is higher than in adipose tissue. The linear structure of the muscle is preserved. The epimysium is represented by a hyperechoic strip, somewhat heterogeneous in thickness, the average value of which is 0.7 mm. The muscle bundle is hypoechoic, heterogeneous in structure, 1.1 mm thick. The perimysium is represented by a hyperechoic strip, with clear uneven contours, up to 0.8 mm thick.

The results of ultrasound examination of the forearm muscles in patients of the reference group with stage 1 occupational myofibrosis and patients of the main group, where the course of myofibrosis (stage 1, according to clinical signs) is complicated by generalized osteoarthritis, are presented in Table 3.

There are statistically significant differences between the median values of epimysium thickness ( $p=0.012$ ), perimysium ( $p<0.001$ ) and muscle bundle thickness ( $p<0.001$ ) in the main and control groups. There is a significant intersection of the interquartile ranges of the thickness of the epimysium and

<sup>2</sup> According to the Russian Federal law from December 28, 2013 No. 426-FZ.

Table 2 / Таблица 2

## Data of clinical examination of reference and main groups

Данные клинического обследования контрольной и основной групп

Показатель Index	Reference group / Контрольная группа n = 97		Main group / Основная группа n = 20	
	absolute number абс. число	frequency of complaints per 100 employees and 95% CI частота жалоб в расчёте на 100 работников и 95% ДИ	absolute number абс. число	frequency of complaints per 100 employees and 95% CI частота жалоб в расчёте на 100 работников и 95% ДИ
<b>Complaints / Жалобы:</b>				
Pain in hand muscles: / Боли в мышцах рук:	97	100 (96.2–100)	20	100 (83.9–100)
permanent (at rest) / постоянные (в покое)	72	74.2 (64.7–81.9)	13	65 (43.3–81.9)
non-permanent / непостоянные:	25	25.8 (18.1–35.3)	7	35 (18.1–56.7)
at the beginning of the work / в начале работы	0	0 (0–3.8)	0	0 (0–16.1)
at the end of the work / в конце работы	25	25.8 (18.1–35.3)	7	35 (18.1–56.7)
Pain in 3 or more joints / Боли в трёх и более суставах	0	0 (0–3.8)	20	100 (83.9–100)
Stiffness in the joints / Скованность в суставах	0	0 (0–3.8)	14	70 (48.1–85.5)
<b>Changing the strength in hands / Изменение силы в руках:</b>				
reduced / снижена	93	95.9 (89.9–98.4)	18	90 (69.9–97.2)
not changed / не изменена	4	4.1 (1.6–10.1)	2	10 (2.8–30.1)
<b>Violation of fine motor skills of the hands / Нарушение мелкой моторики рук:</b>				
yes / есть	72	74.2 (64.7–81.9)	17	85 (64.0–94.8)
no / нет	25	25.8 (18.1–35.3)	3	15 (5.2–36.0)
<b>Objective investigation: / Объективный осмотр:</b>				
<b>Muscles palpation / Пальпация мышц:</b>				
seal / уплотнение	60	61.9 (51.9–70.9)	13	65 (43.3–81.9)
soreness / болезненность	97	100 (96.2–100)	20	100 (83.9–100)
heaviness / тяжесть	35	36.1 (27.2–46.0)	9	45 (25.8–65.8)
nodules / «узелки»	1	1.3 (0.2–5.6)	1	5 (0.9–23.6)
<b>Joints palpation / Пальпация суставов:</b>				
Soreness in 3 or more joints / Болезненность в трёх и более суставах	0	0 (0–3.8)	19	95 (76.4–99.1)
<b>Joint deformation / Деформация суставов:</b>				
yes / есть	0	0 (0–3.8)	14	70 (48.1–85.5)
no / нет	97	100 (96.2–100)	6	30 (14.6–51.9)
<b>Dynamometry (Muscle strength) / Динамометрия (мышечная сила):</b>				
within normal limits / в пределах нормы	19	19.6 (12.9–28.6)	3	15 (5.2–36.0)
moderately reduced / умеренно снижена	69	71.1 (61.4–79.2)	11	55 (34.2–74.2)
significantly reduced / значительно снижена	9	9.3 (5.0–16.7)	6	30 (14.6–51.9)

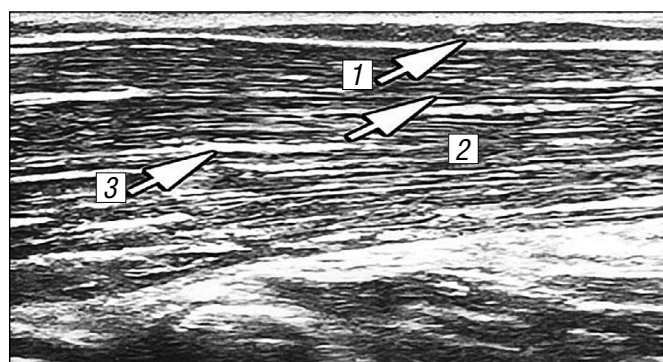


Fig. 1. Ultrasound image of the shoulder muscle (*m. brachioradialis*) in the antero-longitudinal lateral position at the 1<sup>st</sup> stage of myofibrosis. Epimysium (1), muscle bundle (2), perimysium (3).

Рис. 1. Ультразвуковое изображение плечелучевой мышцы (*m. brachioradialis*) в передне-продольной латеральной позиции при 1-й стадии миофиброза. Эпимизий (1), мышечный пучок (2), перимизий (3).

Table 3 / Таблица 3

## Results of ultrasound examination of muscle structures

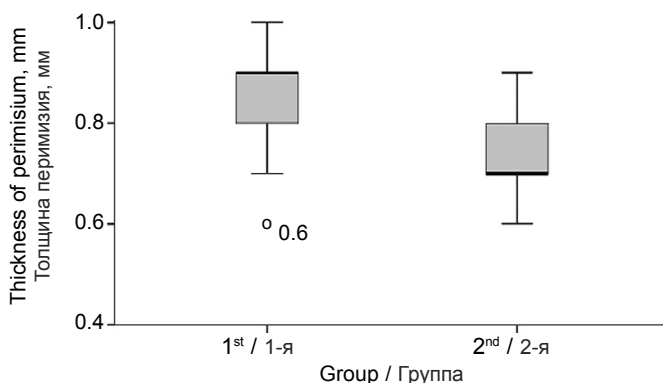
*m. brachioradialis*

Результаты ультразвукового исследования мышечных структур *m. brachioradialis*

Patient group Группа пациентов	Number of patients Число пациентов	Epimysium thickness, mm Толщина эпимизия, мм	Perimysium thickness, mm Толщина перимизия, мм	Thickness of the muscle bundle, mm Толщина мышечного пучка, мм
Reference Контрольная	97	0.7 [0.7–0.8]	0.7 [0.7–0.8]	1.2 [1.1–1.3]
Main Основная	20	0.8 [0.7–0.9]	0.9 [0.8–0.9]	1.1 [1.0–1.2]

Note: median values and interquartile range are indicated.

Примечание. Указаны медианные значения и межквартильный диапазон.



**Fig. 2.** Thickness of the perimysium in the main (1) and control (2) groups (mm).

**Рис. 2.** Толщина перимизия в основной (1) и контрольной (2) группах (мм).

the muscle bundle in the main and reference groups (with the capture of the median of the compared sample), whereas when comparing the results of the study of perimysium thickness, the intersection of the interquartile ranges is not observed (Figure 2), which indicates statistically significant differences not only in the measures of the central trend (medians), but also in the measures of data dispersion.

It should be noted that the median values of epimysium and muscle bundles thickness in both the main and reference groups correspond to the 1<sup>st</sup> stage of myofibrosis, whereas the median thickness of perimysium in the reference group corresponds to the 1<sup>st</sup> stage, and in the main – to the 2<sup>nd</sup> stage. In addition, the 75<sup>th</sup> percentile of epimysium thickness, as well as the 25<sup>th</sup> percentile of muscle bundle thickness in the main group also meet the criteria of stage 2 of myofibrosis.

## Discussion

In 2021, in the structure of the first identified occupational morbidity by the type of economic activity, the largest proportion of occupational pathology cases was noted among employees of mining enterprises – 39.42% [1, 5]. In the structure of the main nosological forms of occupational pathology due to physical overload and overstrain, soft tissue diseases occupy the second place, behind radiculopathy [1, 15–19].

Osteoarthritis is one of the most common and socially significant degenerative diseases of the musculoskeletal system, leading to rapid loss of performance and disability [7, 20]. In the practice of occupational pathologist, the combination of occupational myofibrosis with generalized osteoarthritis is the most common, therefore it is of particular interest.

The aim of the study is to identify the features of the course of this occupational disease in patients with concomitant generalized osteoarthritis.

A total of 117 patients (men) were examined. The average age was  $48 \pm 9.8$  years, the work experience under the influence of harmful production factors was  $12.5 \pm 3.2$  years. The patients

worked in the mining industry and the leading harmful production factor was the severity of the labor process.

The main group consisted of 20 patients with an established diagnosis of stage 1 myofibrosis and concomitant generalized osteoarthritis. The reference group was represented by 97 patients with an established diagnosis of stage 1 occupational myofibrosis.

The study showed that there was no significant difference in complaints and objective examination among patients of the reference and main groups, with the exception of complaints of pain and stiffness in the joints, as well as soreness in joints and joint deformation, which seems logical, having hand osteoarthritis. Laboratory tests also revealed no significant differences in blood and urine parameters.

In our previous studies devoted to the investigation of the forearm muscles structures in patients with myofibrosis of different severity with the help of sonography, we determined that the main ultrasound criteria for the disease are thickening of the epimysium, perimysium and a decrease in the thickness of muscle bundles [12, 13].

In this study the ultrasound examination of the forearm muscles recorded a statistically significant increase of perimysium thickness in patients suffering from occupational myofibrosis and generalized osteoarthritis.

Osteoarthritis is considered as a heterogeneous group of diseases with similar clinical manifestations and outcome, which are based on damage to cartilage, synovial membrane, ligaments, joint capsule, periarticular muscles [21].

One of the mechanisms of the disease development is chronic low-intensity inflammation in the joint due to systemic inflammatory activity [7]. The muscle structures located around the joints suffer both from reactive inflammation, which develops in joints, and from a violation of the kinematic functions of the joint affected by the pathological process [20, 22]. In this regard, it cannot be excluded that the membrane thickening of the muscle bundles is a consequence of the changes described above. However, the role of perimysium in skeletal muscles has not yet been fully studied, so this assumption is debatable.

## Conclusions

Statistically significant differences in the frequency of complaints in the main and control groups were established for two complaints (pain in 3 or more joints, stiffness in the joints), as well as for two clinical signs on palpation of the joints (soreness in 3 and more joints, joint deformation). The frequency of all other complaints in the main and control groups did not have statistically significant differences.

However, during ultrasound examination in patients of the main group, signs corresponding to the transition of myofibrosis to the second stage are noted, which is characterized by a statistically significant increase in the perimysium thickness, as well as a pronounced tendency to increase of epimysium thickness and decrease the muscle bundle thickness. This is important when the disease is associated with profession, allowing patients with a combination of myofibrosis and generalized osteoarthritis to establish a more severe stage of myofibrosis course, indicating a more pronounced degree of occupational work ability loss.

The data obtained should be taken into account for the risk groups creation for the occupational myofibrosis development in persons with generalized osteoarthritis with subsequent dynamic monitoring.

## References

1. State Report «On the state of sanitary and epidemiological welfare of the population in the Russian Federation in 2021». Moscow; 2022. (in Russian)
2. Lutmann A., Jäger M., Griefahn B. *Preventing Musculoskeletal Disorders in the Workplace. Protecting Workers' Health Series: No. 5.* Geneva; 2003. Available at: <https://iris.who.int/bitstream/handle/10665/42651/924159053X.pdf>
3. Takala J., Iavicoli S., Kang S.K., Gagliardi D., Nogueira C., Kocks D., et al. Work-related injuries and diseases, and COVID-19. *Int. J. Labour Res.* 2021; 10(1–2): 23.
4. Surbek K. Über die Verfertigung der Skelettmuskulatur. In: *Frankfurter Zeitschrift für Pathologie.* Frankfurt; 2006: 447–84.
5. Bukhtiyarov I.V. Current state and main directions of preservation and strengthening of health of the working population of Russia. *Meditsina truda i promyshlennaya ekologiya.* 2019; 59(9): 527–32. <https://doi.org/10.31089/1026-9428-2019-59-9-527-532> <https://elibrary.ru/htrksy> (in Russian)
6. Bashketova N.S., Naumova T.N., Volchkova O.V., Gerasimova L.B. Occupational diseases in St. Petersburg. In: *Materials of the Scientific and Practical Conference with International Participation «Medical and Environmental Health Problems of Workers in the North-Western Region and Ways to Solve Them» [Materialy nauchno-prakticheskoy konferentsii s mezhdunarodnym uchastiem «Mediko-ekologicheskie problemy zdorov'ya rabotayushchikh Severo-Zapadnogo regiona i puti ikh resheniya»*. St. Petersburg; 2014: 10–4. (in Russian)
7. Uryas'ev O.M., Zaigrova N.K. Osteoarthritis: pathogenesis, diagnostics, therapy. *Zemskiy vrach.* 2016; (1–2): 27–35. <https://elibrary.ru/vwgtpt> (in Russian)

8. Pilipovich A.A. Osteoarthritis: pathogenetic and therapeutic aspects. *Russkiy Meditsinskiy Zhurnal*. 2016; (7): 464–8. <https://elibrary.ru/vwgtpb> (in Russian)
9. Clinical recommendations: Management of patients with osteoarthritis and comorbidity in general medical practice. Moscow; 2016. (in Russian)
10. Avtukhova Z.M. The experience of using ultrasound in the diagnosis of occupational myofibrosis. *Ul'trazvukovaya i funktsional'naya diagnostika*. 2002; (2): 293–4. (in Russian)
11. Plakuev A.N. The significance of ultrasonic examination in diagnosis of professional fibromyositis. *Ekologiya cheloveka*. 2003; (6): 22–6. <https://elibrary.ru/hrtkvp> (in Russian)
12. Ulanovskaya E.V., Karabanovich E.V., Kuprina N.I. Experience in the use of magnetic resonance imaging in the diagnosis of professional myofibrosis. *Meditsina truda i promyshlennaya ekologiya*. 2019; 59(9): 782–4. <https://doi.org/10.31089/1026-9428-2019-59-9-782-783> <https://elibrary.ru/iaifii> (in Russian)
13. Ulanovskaya E.V., Trofimova T.N., Shilov V.V., Ornitson E.Yu., Andreenko O.N. The possibilities of ultrasound study in early occupational myofibrosis revealing. *Luhevaya diagnostika i terapiya*. 2016; (3): 69–72. <https://elibrary.ru/wmghex> (in Russian)
14. Dalakas M.C. Viral related muscle disease. In: Engel A.G., ed. *Myology*. New York: McGrawHill; 2004.
15. House R., Wills M., Liss G., Switzer-McIntyre S., Manno M., Lander L. Upper extremity disability in workers with hand-arm vibration syndrome. *Occup. Med. (Lond.)*. 2009; 59(3): 167–73. <https://doi.org/10.1093/occmed/kqp016>
16. Abareshi F., Yarahmadi R., Solhi M., Farshad A.A. Educational intervention for reducing work-related musculoskeletal disorders and promoting productivity. *Int. J. Occup. Saf. Ergon.* 2015; 21(4): 480–5. <https://doi.org/10.1080/10803548.2015.1087729>
17. Yasobant S., Rajkumar P. Work-related musculoskeletal disorders among health care professionals: A cross-sectional assessment of risk factors in a tertiary hospital, India. *Indian J. Occup. Environ. Med.* 2014; 18(2): 75–81. <https://doi.org/10.4103/0019-5278.146896>
18. Cromie J.E., Robertson V.J., Best M.O. Work-related musculoskeletal disorders in physical therapists: prevalence, severity, risks, and responses. *Phys. Ther.* 2000; 80(4): 336–51. <https://doi.org/10.1093/ptj/80.4.336>
19. Milhem M., Kalichman L., Ezra D., Alperovitch-Najenson D. Work-related musculoskeletal disorders among physical therapists: A comprehensive narrative review. *Int. J. Occup. Med. Environ. Health*. 2016; 29(5): 735–47. <https://doi.org/10.13075/ijomh.1896.00620>
20. Shostak N.A., Pravdyuk N.G., Klimenko A.A., Kondrashov A.A., Timofeev V.T. Osteoarthritis and associated pathology-clinical and pathogenetic associations. *Russkiy Meditsinskiy Zhurnal. Meditsinskoe obozrenie*. 2019; 3(11–2): 44–7. <https://elibrary.ru/uedlqn> (in Russian)
21. Atiquzzaman M., Karim M.E., Kopec J., Wong H., Anis A.H. Role of nonsteroidal antiinflammatory drugs in the association between osteoarthritis and cardiovascular diseases: a longitudinal study. *Arthritis Rheumatol.* 2019; 71(11): 1835–43. <https://doi.org/10.1002/art.41027>
22. Da Costa B.R., Vieira E.R. Risk factors for work-related musculoskeletal disorders: A systematic review of recent longitudinal studies. *Am. J. Ind. Med.* 2010; 53(3): 285–323. <https://doi.org/10.1002/ajim.20750>

### Литература

(п.п. 2–4, 14–19, 21, 22 см. References)

1. Государственный доклад «О состоянии санитарно-эпидемиологического благополучия населения в Российской Федерации в 2021 году». М.; 2022.
5. Бухтияров И.В. Современное состояние и основные направления сохранения и укрепления здоровья работающего населения России. *Медицина труда и промышленная экология*. 2019; 59(9): 527–32. <https://doi.org/10.31089/1026-9428-2019-59-9-527-532> <https://elibrary.ru/htkrsy>
6. Башкетова Н.С., Наумова Т.Н., Волчкова О.В., Герасимова Л.Б. Профессиональные заболевания в Санкт-Петербурге. В кн.: *Материалы научно-практической конференции с международным участием «Медико-экологические проблемы здоровья работающих Северо-Западного региона и пути их решения»*. СПб.; 2014: 10–4.
7. Урясьев О.М., Заигрова Н.К. Остеoarthritis: патогенез, диагностика, лечение. *Земский врач*. 2016; (1–2): 27–35. <https://elibrary.ru/vwgtpb>
8. Пилипович А.А. Остеoarthritis: патогенетические и терапевтические аспекты. *Русский Медицинский Журнал*. 2016; 24(7): 464–8. <https://elibrary.ru/wcd1rg>
9. Ведение больных с остеоarthritis и коморбидностью в общей врачебной практике: Клинические рекомендации. М.; 2016.
10. Автухова З.М. Опыт применения ультразвукового исследования в диагностике профессионального миофиброза. *Ультразвуковая и функциональная диагностика*. 2002; (2): 293–4.
11. Плакуев А.Н. Значение ультразвукового исследования в диагностике профессионального фибромиозита. *Экология человека*. 2003; (6): 22–6. <https://elibrary.ru/hrtkvp>
12. Улановская Е.В., Карабанович Е.В., Куприна Н.И. Опыт применения магнитно-резонансной томографии в диагностике профессионального миофиброза. *Медицина труда и промышленная экология*. 2019; 59(9): 782–4. <https://doi.org/10.31089/1026-9428-2019-59-9-782-783> <https://elibrary.ru/iaifii>
13. Улановская Е.В., Трофимова Т.Н., Шиллов В.В., Орнитсон Э.Ю., Андренко О.Н. Возможности метода ультразвукового исследования в ранней диагностике профессионального миофиброза. *Лучевая диагностика и терапия*. 2016; (3): 69–72. <https://elibrary.ru/wmghex>
20. Шостак Н.А., Правдюк Н.Г., Клименко А.А., Кондрашов А.А., Тимофеев В.Т. Остеoarthritis и ассоциированная патология – клинико-патогенетические взаимосвязи. *Русский Медицинский Журнал. Медицинское обозрение*. 2019; 3(11–2): 44–7. <https://elibrary.ru/uedlqn>